

Amniotic membrane: Expanding thoughts on when to use these products

by Liz Hillman EyeWorld Staff Writer

An article in the May 2017 issue of EyeWorld provided a brief history of the use of amniotic membrane in ophthalmology and delved into how some physicians are using amniotic membrane to improve the ocular surface prior to cataract surgery. This article expands perspectives on this topic and explores how amniotic membrane can be used in other applications for ocular healing.

Barry Schechter, MD, director of the cornea and cataract service, Florida Eye Microsurgical Institute, Boynton Beach, Florida, said amniotic membrane (AM) has been “invaluable” in many therapeutic areas of ophthalmology.

“It has been successful in facilitation of epithelialization, maintenance of normal cellular phenotypes, and reduction of inflammation, vascularization, and scarring when treating corneal ulcers; in treatment of corneal erosions; and extremely helpful in surgical treatment of ocular surface disorders. I have been utilizing AM in its various forms for more than 15 years,” Dr. Schechter said.

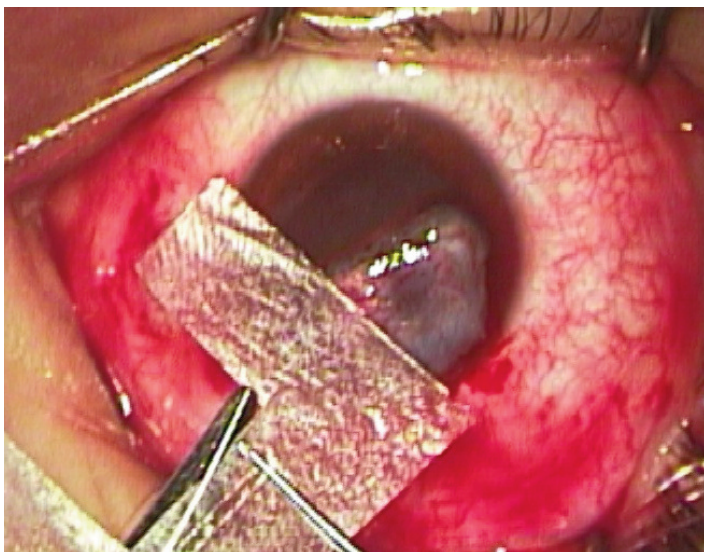
“Any treatment that necessitates the prolongation and maintenance of epithelial stem cells, promotion of conjunctival goblet cell differentiation, and exclusion of inflammatory cells with anti-protease activities would benefit from the inclusion of AM,” he said.

“Any treatment that necessitates the prolongation and maintenance of epithelial stem cells, promotion of conjunctival goblet cell differentiation, and exclusion of inflammatory cells with anti-protease activities would benefit from the inclusion of AM,” he said.

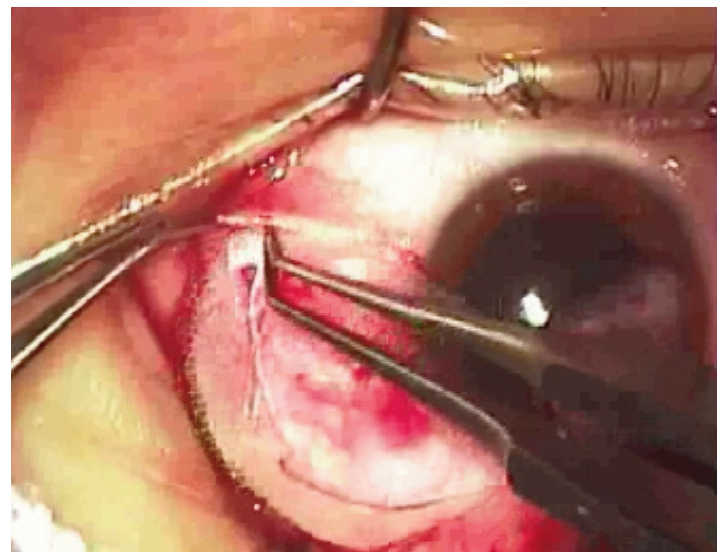
John Hovanesian, MD, Harvard Eye Associates, Laguna Hills, California, a cornea specialist, said the most com-

mon condition he treats as it pertains to AM is pterygium. Dr. Hovanesian said his use of amniotic membrane to promote healing and prevent recurrence in pterygia cases dates back to 2004 when he was looking for a method gentler than mitomycin-C.

“Amniotic membrane provided that answer,” he said. “I started doing a procedure that involved doing a conjunctival autograft but additionally taking amniotic membrane and placing it just in the subconjunctival space surrounding that graft. ... Tuck it in underneath the surrounding conjunctiva—it’s like a protective barrier in that space—to prevent recurrence. Then you glue down the graft in the normal fashion. The graft is not sitting on top of amniotic membrane; it’s sitting on top



Dehydrated human amniotic membrane is cut into a C-shaped graft.



The graft is tucked into the subconjunctival space to provide its anti-fibrotic effects to Tenon’s fascia, from which pterygium recurrence might arise.

Source: John Hovanesian, MD

“Any treatment that necessitates the prolongation and maintenance of epithelial stem cells, promotion of conjunctival goblet cell differentiation, and exclusion of inflammatory cells with anti-protease activities would benefit from the inclusion of AM.”

—Barry Schechter, MD

of sclera as it usually is, but then around it in the subconjunctival space is this amnion. The rationale for that technique is when we think about recurrence of pterygium, it doesn't come from the bare sclera site, it comes from the tissue underneath the surrounding conjunctiva,” Dr. Hovanesian explained.

A non-comparative study coauthored by Dr. Hovanesian published in the Canadian Journal of Ophthalmology detailed use of amniotic membrane in 101 pterygia cases.¹ Recurrence using this technique at 6 months of follow-up was 1%. Dr. Hovanesian said other reports suggest recurrence rates without amniotic membrane being closer to 5%.

Similarly, research coauthored by Dr. Schechter, presented at the 2017 ASCRS•ASOA Symposium & Congress, involving 493 eyes in an ethnically diverse population—8% Caribbean/African American, 27% Hispanic, and 15% Caucasian/Asian—found a 1.22% recurrence rate with the adjunctive use of amniotic membrane for conjunctival autograft for pterygia cases.²

“The importance of the study is in showing that these patients who phenotypically have a much higher rate of pterygium recurrence did extremely well with a low recurrence rate when

conjunctival stem cell grafting was augmented by the use of amniotic membrane,” Dr. Schechter said.

Drs. Schechter and Hovanesian said they've used cryopreserved and dehydrated amniotic membranes, finding both varieties efficacious. Dr. Schechter said he prefers cryopreserved AM when he wants the membrane to be incorporated into the healing tissue, for example in cases of Stevens-Johnson syndrome or in neurotrophic disease. When he wants AM to function as a scaffold for reepithelialization, he prefers dehydrated AM.

“As far as healing, I think they both work well,” Dr. Hovanesian said, adding that in some cases he thinks thinner dehydrated membranes held in place with a soft contact lens can be easier to deal with than the cryopreserved products that have a self-retaining ring, although there are times self-retention is an advantage as well.

Research presented as a poster at the 2015 ASCRS•ASOA Symposium & Congress compared Prokera (Bio-Tissue, Doral, Florida), a cryopreserved amniotic membrane, and AmbioDisk (IOP Ophthalmics/Katena, Denville, New Jersey), a dehydrated amniotic membrane, for different indications of corneal epithelial defects.³ Of the 40 eyes in the study, 28 received Prokera and 12 received AmbioDisk. Indications for AM use were similar

among the two groups, the study authors reported, and rates of complete success for Prokera vs. AmbioDisk were 28.6% and 41.7%, partial success 57.1% and 50%, and failure 14.3% and 8.3%, respectively.

“Whatever the product is, it's a tool like anything else and there's a right application for it and there are many wrong applications,” Dr. Hovanesian said.

One of the latter is using amniotic membrane to treat “run of the mill” dry eye, Dr. Hovanesian said.

“The use of amniotic membrane in that application is rarely justified,” Dr. Hovanesian said. “Amniotic membrane is effective for getting non-healing defects of the cornea to heal. It does not cure dry eye.”

Dr. Hovanesian said the underlying cause of dry eye needs to be addressed first. If the cause has been addressed and there are still healing problems—such as if there is a neurotrophic cornea or limbal stem cell deficiency preventing complete healing—then AM could be justified.

“It's for unique applications, not for every patient with dry eye,” Dr. Hovanesian said. EW

References

1. Hovanesian J and Shusko A. Pterygium excision with conjunctival autograft and subconjunctival amniotic membrane as antirecurrence agents. *Can J Ophthalmol.* 2016;51:412–16.
2. Schechter B and Shusko A. Outcomes of pterygium excision with a conjunctival autograft and subconjunctival amniotic membrane graft as a prophylactic anti-recurrence agent in ethnically diverse populations. 2017 ASCRS•ASOA Symposium & Congress.
3. Gorski M, et al. Comparison of 2 office-based sutureless amniotic membrane transplantation modalities for ocular surface disorders. 2015 ASCRS•ASOA Symposium & Congress.

Editors' note: Dr. Hovanesian has financial interests with Katena. Dr. Schechter has no financial interests related to his comments.

Contact information

Hovanesian: drhovanesian@harvardeye.com
Schechter: bdsch77@aol.com